

**PATIENT**

Beethoven Followwill

SPECIES

Feline

BREED

DSH

SEX

Male Neutered

AGE

8 years

WEIGHT

14lbs

INTERPRETED BYMaggie Machen Lamy,
DVM, DACVIM
(Cardiology)**IMAGING PERFORMED BY**

Sarah Pender, CVT

HOSPITAL NAME

SVS Imaging QC

REFERRING VET

Dr. Flickinger

INVOICE

21452

DATE

10/11/21

PRESENTING CLINICAL SIGNS

History: Asymptomatic. Grade II murmur found on routine exam. Positive BNP test.

ECHOCARDIOGRAM FINDINGS

2D, m-mode, color flow and doppler imaging is available. The left ventricular wall is borderline normal in dimension. There is a diffusely hyperechoic endocardium consistent with fibrosis and remodeling. The endocardium also appears remodeled. The MV appears normal. An obstruction is not captured on 2D or doppler; however, color flow suggests an intermittent LVOTO (suspected to be captured on Spectral as well). Mild eccentric MR that appears intermittent. The left atrium is normal in size. The right atrium is normal in size. The right ventricle appears normal. Blood flow through the RVOT is normal in velocity. Trace TR. There is no pleural or pericardial effusion seen. There are no obvious cardiac tumors.

CARDIAC CHART

FELINE CARDIAC PARAMETERS	BODY WEIGHT (kg)	HR (BPM)	IVSd (cm) (Moise, Pipers)	LVIDd (cm) (Moise, Pipers)	LWVd (cm) (Moise, Pipers)	FS (%)	EF (%)
NORMAL PARAMETER	-----	150-240	0.35-0.55	<2 (mean 1.5)	3.5-0.55	35-67	80-100
PATIENT	6.4	196	0.56	1.47	0.57	42	87
FELINE CARDIAC PARAMETERS	LA/AO (Boon)	LA/AO HEART BASE (Swe) (Abbott)	LA 2D short axis Base view (cm) (Abbott)		LVOT VEL (m/s)	RVOT VEL (m/s)	E max (m/s)
NORMAL	<1.5	<1.3	<1.2		<1.6	<1.3	<0.9
PATIENT	1.0	1.2	1.3			1.3	NM

**Note: All measurements based upon multi-modal images and methods. An average value is reported.*
 Adapted from June Boon, Veterinary Echocardiography, 1998
 Abbott J & MacLean H JVIM 2006;20: 111-119, Moise et al. Am J Vet Res 47:1476, 1986. Pipers et al. Am J Vet Res 40:882, 1979.

INTERPRETATION OF THE FINDINGS & FURTHER RECOMMENDATIONS

Overtly normal cardiac structure and function. The murmur is due to a dynamic LVOT obstruction and mitral regurgitation, secondary to abnormal valve movement and elevated heart rates. This is presumptive as Doppler flows were not confirmed. There is also borderline LV wall dimensions, in addition to mild remodeling and fibrosis of the left ventricular wall. These changes may be indicative of early cardiac disease (HOCM) or may simply represent a normal variant. Serial echocardiography will be necessary to determine progression and clinical relevance of both findings. A screening BP and T4 are recommended.

In patients with persistent LVOT obstruction and an elevated pressure gradient, a beta blocker is often prescribed to lower heart rate and decrease the gradient. In this patient with a mild obstruction and borderline normal LA/LV dimensions, no medications are clearly indicated.

This does not assess the reported arrhythmia and an ECG is highly recommended before proceeding with anesthesia.

IMAGING PERFORMED BY

svsmobileimaging.com 309 - 737 - 3070



Clinical Sonography & Telemetry

EDUCATIONAL TELECONSULTATION SERVICES™

1-800-838-4268 info@sonopath.com SonoPath.com

PATIENT

Beethoven Followwill

SPECIES

Feline

BREED

DSH

SEX

Male Neutered

AGE

8 years

WEIGHT

14lbs

INTERPRETED BYMaggie Machen Lamy,
DVM, DACVIM
(Cardiology)**IMAGING PERFORMED BY**

Sarah Pender, CVT

HOSPITAL NAME

SVS Imaging QC

REFERRING VET

Dr. Flickinger

INVOICE

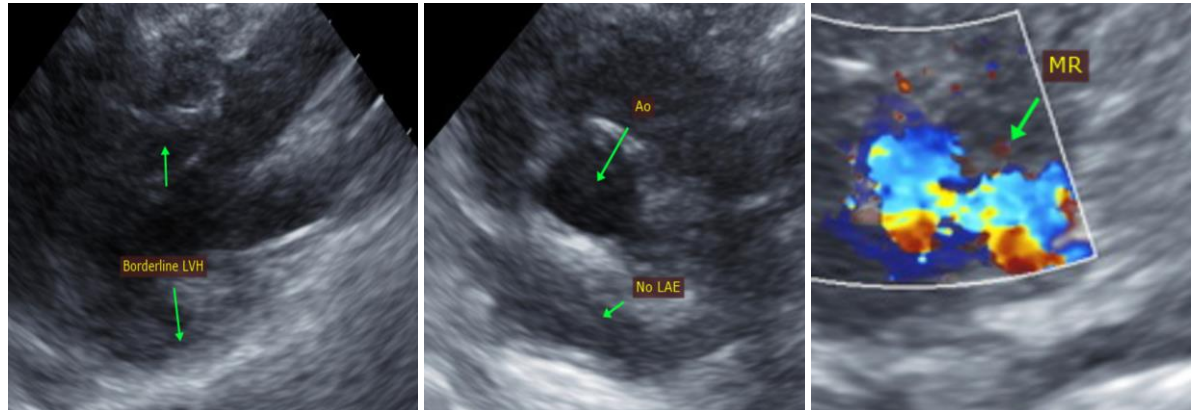
21452

DATE

10/11/21

From a structural standpoint, anesthetic risk is currently low. Avoid heart rate stimulating drugs (atropine, glycopyrrolate) unless clinically necessary. Avoid vasodilators such as acepromazine as this can worsen obstruction. Judicious IV fluid rates are recommended to avoid fluid overload in this patient with diastolic dysfunction.

A recheck echocardiogram is recommended in 6-12 months, sooner if any clinical signs arise.

IMAGES

The information and recommendations provided are based on the images presented by the referring veterinarian. No evaluation can be communicated regarding pathology that was not visible in the image/video clips provided.

Thank you for this referral. If the clinical or image interpretation does not parallel your findings or if I can be of any further assistance, please contact me.

Maggie Machen Lamy, DVM
Diplomate of the American College of Veterinary Internal Medicine (Cardiology)
info@sonopath.com